

# Treatment of Depression with Botulinum Toxin A: A Case Series

ERIC FINZI, MD, PhD,\*† AND ERIKA WASSERMAN, PhD‡

---

**BACKGROUND** Major depression is a common and serious disease that may be resistant to routine pharmacologic and psychotherapeutic treatment approaches.

**OBJECTIVE** To evaluate the efficacy of botulinum toxin A treatment of glabellar frown lines in treating patients with major depression, using a small open pilot trial.

**METHODS** Patients who met DSM-IV criteria for ongoing major depression in spite of pharmacologic or psychotherapeutic treatment were evaluated with the Beck Depression Inventory II (BDI-II) before receiving botulinum toxin A to their glabellar frown lines. Two months later, all patients were re-evaluated clinically and with the BDI-II.

**RESULTS** Ten depressed patients were treated with botulinum toxin A, and 9 of 10 patients were no longer depressed 2 months after treatment. The tenth patient had an improvement in mood.

**CONCLUSION** To our knowledge, these are the first reported cases of depression treated with botulinum toxin A.

*Dr. Finzi has applied for a patent using botulinum toxin A to treat depression.*

---

An estimated 10 to 25% of women and 5 to 10% of men will develop a major depressive disorder at some time in their lives.<sup>1</sup> Although different pharmacologic and psychotherapy treatment approaches exist, a significant portion of depressed patients is resistant to treatment. Such individuals are often simply unable to function in everyday life situations, and there is a serious risk of suicide among such individuals. In addition, troubling side effects, such as gastrointestinal disturbances or loss of libido, may be experienced with existing antidepressants. Thus, there has been a continual search for effective new treatments for this serious health problem.

Depression is often associated with psychomotor abnormalities, such as increased or retarded motor activity. Many depressed individuals can also be recognized by their depressed facial expression, in which the facial muscles create a distressed or sad appearance. For example, the brow may be furrowed, the medial ends of the eyebrows may be raised, and the angles of the mouth may be lowered, such that the facial appearance is recognizably sad and/or anxious.<sup>2</sup>

There is a body of evidence that suggests that the facial expression of emotion may play a causal role in the subjective experience of emotion.<sup>3</sup> We initiated a small

open pilot trial to determine whether inhibiting the expression of facial frowning commonly associated with depression could help ameliorate depressive symptoms. We describe 10 depressed patients who were treated with botulinum toxin A for their glabellar frown lines. Nine of the 10 patients experienced a resolution of their depression symptoms, while the tenth patient experienced an improvement in mood.

## Methods

Patients between the ages of 18 and 65 who felt depressed were recruited. All patients gave informed consent, and the study protocol conformed to the ethical

---

\*Dermatology & Cosmetic Surgery Associates, Greenbelt, Maryland; †Chevy Chase Cosmetic Center, Chevy Chase, Maryland; ‡William Stixrude and Associates, Bethesda, Maryland

guidelines of the 1975 Declaration of Helsinki.

In order to minimize the effect of confounding variables on patient outcomes, and to minimize the potential for secondary gain for women to potentially obtain a "treatment for depression" while receiving a cosmetic procedure, patients were entered into the study only if they met the following criteria:

- (1) There had been no change in their medication or psychotherapy treatment regimen during the 3 months before receiving botulinum toxin A treatment.
- (2) In order to be eligible for botulinum toxin A treatment, all patients were evaluated by a clinical psychologist (E. W.) for depressive symptomatology and needed to meet DSM-IV criteria for major depression.
- (3) Only patients with a Beck Depression Inventory II (BDI-II) (Harcourt Brace & Company, San Antonio, TX, USA) score of 20 or greater (moderate to severe depression) were eligible.
- (4) In view of the outpatient treatment setting of the study, we excluded all patients who presented with psychotic features on initial evaluation.
- (5) Only patients who had never received botulinum toxin A previously were entered.

- (6) Patients needed to have at least a 6-month history of depression.

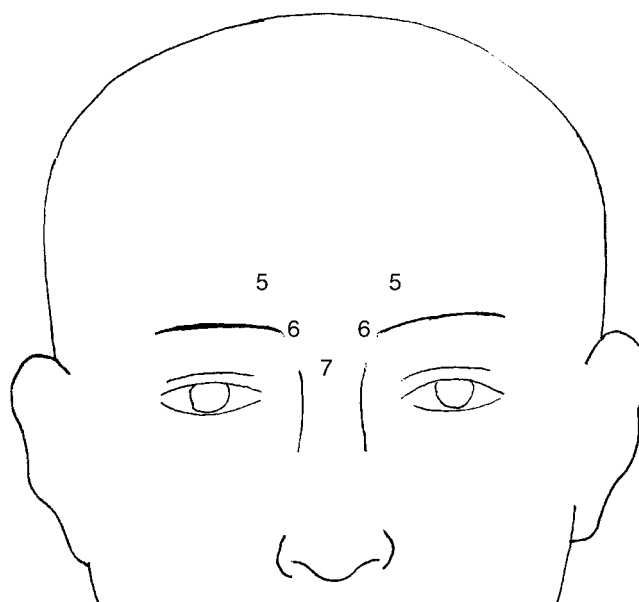
The BDI has become one of the most widely accepted instruments for detecting depression and assessing its severity<sup>4</sup> since its introduction in 1961.<sup>5</sup> The BDI was revised and modernized in 1994. The new version, BDI-II, was developed as an indicator of the presence and degree of depressive symptoms consistent with the American Psychiatric Association's Diagnostic and Statistical Manual of Mental Disorders, fourth edition (DSM-IV; 1994).

Thirteen patients were screened for the open pilot trial. Ten patients met the study criteria, and, after obtaining informed consent, they were treated by injection with 29 units of botulinum toxin A into the procerus and corruga-

tor supercillii frown muscles (Figure 1).<sup>6</sup> Patients were then re-evaluated for depression by a clinical psychologist 2 months later and were given a repeat BDI-II test. The absence of glabellar frown muscle activity was confirmed at that time as well.

## Results

Treatment of all patients with botulinum toxin A was well tolerated by all patients, with no notable side effects. The study population consisted of 10 female patients ranging from 36 to 63 years in age (Table 1). The length of time for which the patients had been depressed ranged from 2 to 17 years, with a median of 3.5 years. Seven of the 10 patients had been tried on one or more antidepressant medications and they continued to have persistent ma-



**Figure 1.** Botulinum toxin A dose and placement used to treat patients.

**TABLE 1. Summary of Patient Characteristics and Response of Depression to Treatment with Botulinum Toxin A**

Patient No.	Age (Years)/ Sex	Previous Treatments	Current Treatment	Duration of Depression (Years)	Pretreatment BDI-II score	Post-treatment BDI-II score
1	62/f	B, P, Psy	B	11	27	5
2	62/f	F, P, R, Psy	P, R, Psy	7	30	7
3	37/f	B, P	—	5	30	2
4	36/f	B, F, V, Psy	F	2	41	6
5	47/f	B, D, G	B, D, G	17	46	33
6	63/f	E	—	2	22	8
7	38/f	—	—	1	27	0
8	63/f	B, Psy	B	10	21	4
9	38/f	—	—	2	31	2
10	38/f	—	—	1	32	14

B, Bupropion, D, divalproex sodium, E, escitalopram oxalate, F, fluoxetine, G, gabapentin, P, paroxetine, Psy, psychotherapy, R, remeron, V, venlafaxine.

major depression before their entrance into the study (Table 1). Psychiatric treatments at the time of botulinum toxin A administration are listed in Table 1. Nine of the patients had a unipolar depression and one patient had a bipolar disorder.

All patients had an improvement in their mood at their 2-month evaluation. Nine patients were no longer clinically depressed by DSM-IV criteria or by their BDI-II test scores (Table 1). Patient number 9 remained depressed, but felt better. This patient had a history of bipolar disorder. The clinical history of four representative patients is described below.

### Case 1

The patient is a 62-year-old female who was initially diagnosed with depression 11 years ago. The patient began weekly psychotherapy at that time. Ten years ago, she began taking bupropion,

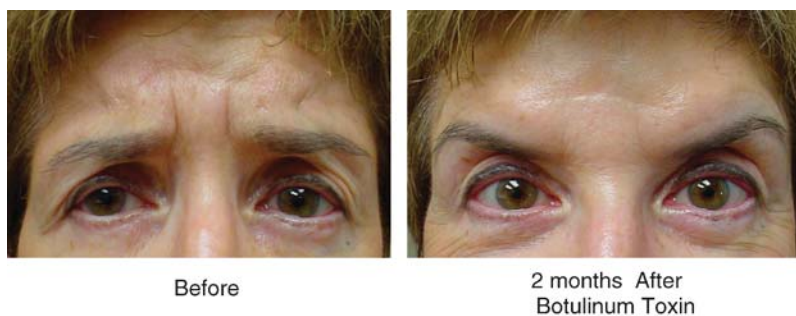300 mg daily, for her depression, but she continued to feel depressed. Clinical evaluation immediately before her initial botulinum toxin A treatment revealed that she was clinically depressed. Her pretreatment BDI-II score was 27. Clinical assessment 2 months after botulinum toxin A treatment showed that she was no longer depressed, and her follow-up BDI-II score was 5. Figure 2 demonstrates the dramatic change in at-rest facial expression after botulinum toxin A treatment. Note how the patient appears dramatically happier after her frown at rest had disappeared

along with the lowering of the medial ends of the eyebrows.

The patient stated, “my life did a 360° turnaround” after botulinum toxin A treatment. She applied for and started a new job and “re-kindled a 47-year-old romance.”

### Case 2

The patient is a 62-year-old female who was first diagnosed with depression 7 years ago, following an injury and subsequent inability to work. Six years ago, she was begun on fluoxetine by her psychiatrist. Two years ago,



**Figure 2.** Elimination of depressed facial expression with botulinum toxin A.

she lost her mother and began seeing a therapist once weekly. Fluoxetine was discontinued, and the patient was started on 50 mg of paroxetine daily in addition to 30 mg of remeron. At the time of treatment with botulinum toxin A, she was clinically depressed and her BDI-II score was 30. Two months after treatment, she was no longer clinically depressed and her BDI-II score was 7. She was next seen back in follow-up 8 months later, during which her botulinum toxin A had completely worn off and a persistent frown at rest was noted. Re-evaluation revealed that her depression had recurred and her BDI-II score was 36. She was again treated with botulinum toxin A. Re-evaluation 3 months later revealed that she was no longer clinically depressed and her BDI-II score was 12. She attributed her improvement in mood completely to botulinum toxin A, as there had been no major changes in her life during the last year.

### Case 3

The patient is a 37-year-old female who first became depressed 5 years ago, after the death of her mother. She began psychotherapy once weekly and paroxetine at that time. She failed to experience improvement, and 6 months later paroxetine was discontinued and bupropion 300 mg daily was started. She again failed to experience significant improvement, and she discontinued medication and therapy 3 years ago. She was clinically

depressed at her initial visit, and her preoperative BDI-II score was 30. Two months after treatment, her depression had completely lifted, and her BDI-II score was 2.

### Case 4

The patient is a 36-year-old female who became depressed 2 years ago and was initially started on bupropion, then switched to venlafaxine. Six months ago, venlafaxine was discontinued, and the patient was started on 40 mg of fluoxetine once a day. Clinical assessment at the time of botulinum toxin A treatment revealed depression, and her pretreatment BDI-II score was 41. Two months after receiving botulinum toxin A, she was no longer clinically depressed, and her post-treatment BDI-II score was 6.

The mean pretreatment BDI-II score for all patients was 30.7, versus 8.1 post-treatment,  $p < .005$ , Wilcoxon signed rank test.

It is interesting to note that when the botulinum toxin A was allowed to completely wear off in patient 2, she experienced a relapse of her depression, and her at-rest frown returned. Her second treatment with botulinum toxin A led to resolution of her depressive symptoms again.

In summary, 9 of 10 clinically depressed individuals were no longer depressed 2 months after treatment of their glabellar frown complex with botulinum toxin A.

### Discussion

Patients with depression experience significant morbidity and increased mortality from their disease. Although numerous antidepressant medications are currently in use, many patients continue to suffer from major affective depression some time in their lives. We report on 10 depressed patients who were treated with botulinum toxin A for their glabellar frown lines. Nine of the ten experienced resolution of their depression symptoms. The patient who had only a partial response was bipolar.

The hypothesis that muscle and skin movement in the face may, to some extent, contribute to our own mood and emotion was suggested by the 18th-century German playwright Gotthold Lessing: "When the actor properly imitates all the external signs ... and all the bodily alterations which ... are expressions of a particular [inner] state, the resulting impression will automatically induce a state in his soul that properly accords with his own movements, posture and vocal tone."<sup>7</sup> Charles Darwin noted: "The free expression, by outward signs, of an emotion intensifies it. On the other hand repression, as far as this is possible, of all outward signs softens our emotions. He who gives way to violent gestures will increase his rage: he who does not control the signs of fear will experience fear in a greater degree and he who remains passive when overwhelmed with grief loses his

best chance of recovering elasticity of mind.”<sup>2</sup>

More recently, Adelman and Zajonc<sup>3</sup> showed that subjects made to smile while watching a cartoon actually found the cartoon funnier. Jonathan Cole used patients with Mobius’ syndrome (inability to move facial muscles) to provide further insight into this feedback model. His Mobius patient James felt he was “living a life of the mind, ... and “that [his] mind is not easily able to communicate its thoughts or even its feelings.” James went on to say, “I ... think happy or I think sad, not ... actually feeling happy or feeling sad.”<sup>8</sup> Cole goes on to conclude that “losing facial animation meant not only losing expression and communication with others but led to a reduced intensity and delineation of feeling within oneself.”<sup>9</sup>

Increased frown muscle activity has been associated with depression and has been used as an independent predictor of treatment outcome.<sup>10,11</sup> Patients who have had their frown lines treated with botulinum toxin A are perceived by others to appear happier.<sup>12</sup> Our study is the first to suggest that the enhancement of the facial expres-

sion of happiness may also make treated individuals feel happier.

The use of botulinum toxin A to correct glabellar frown lines is an effective and popular cosmetic procedure, with more than 1 million treatments per year in the United States alone.<sup>13</sup>

These preliminary results are encouraging, but much larger randomized, double-blind, and placebo-controlled clinical trials are required to define a possible role for botulinum toxin A in the treatment of clinical depression.

*Acknowledgments* We thank Jennifer Stewart for her help with the study patients and VassarStats for providing the Wilcoxon signed rank test.

## References

1. American Psychiatric Association Website. Available at <http://www.psych.org>. Accessed March 5, 2004.
2. Darwin C. The expression of the emotions in man and animals. Introduction, afterword and commentaries. by Ekman P. 3rd ed. London: Oxford University Press, 1998.
3. Adelman PK, Zajonc RB. Facial efference and the experience of emotion. *Ann Rev Psychol* 1989;40:249–80.
4. Beck AT, Steer RA, Garbin MG. Psychometric properties of the Beck Depression Inventory: twenty-five years of evaluation. *Clin Psych Rev* 1988;8:77–100.
5. Beck AT, Ward CH, Mendelson M, Mock J, Erbaugh J. An inventory for measuring depression. *Arch Gen Psychiatry* 1961;4:561–71.
6. Carruthers A, Carruthers J. Clinical indications and injection technique for the cosmetic use of botulinum A exotoxin. *Dermatol Surg* 1998;24:1189–94.
7. Lessing B. Quoted in Fridlund A.J. Evolution and facial action in reflex, social motive and paralanguage. *Biol Psychol* 1991;32:3–100.
8. Cole J. *About face*. Cambridge, MA: MIT Press; 1998. p. 126–7.
9. Cole J. *About face*. Cambridge, MA: MIT Press; 1998. p. 150.
10. Carney RM, Hong BA, O’Connell MF, Amado H. Facial electromyography as a predictor of treatment outcome in depression. *Br J Psychiatry* 1981;138:485–9.
11. Greden JF, Genero N, Price HL. Agitation-increased electromyogram activity in the corrugator muscle region: a possible explanation of the “Omega sign”? *Am J Psychiatry* 1985; Mar;142(3): 348–51.
12. Heckmann M, Teichmann B, Schroder U, Sprengelmeyer R, Ceballos-Baumann AO. Pharmacologic denervation of frown muscles enhances baseline expression of happiness and decreases baseline expression of anger, sadness, and fear. *J Am Acad Dermatol* 2003;49: 213–6.
13. Carruthers A. Botulinum toxin type A: history and current cosmetic use in the upper face. *Dis Mon* 2002;48:299.

Address correspondence and reprint requests to: Eric Finzi, MD, PhD, 8401 Connecticut Ave., Suite 210, Chevy Chase, MD 20815, or email: [efinzi@starpower.net](mailto:efinzi@starpower.net)

## COMMENTARY

This paper is a report, albeit anecdotal, of the use of BTX-A for a new indication. We have all seen individuals whose mood has changed positively following BTX-A injection in the brow area. The authors of this paper have attempted to document this change.

However, this report must be considered anecdotal as there were no appropriate methods of control utilized. In addition, there were other methodological weaknesses including limited follow-up, lack of randomization, the absence of blind evaluation, and especially the small number of individuals included. The method evaluating depression should be more rigorous. Patients' self-report of depressive symptoms by administration of the BDI-II introduces a significant self-report bias. This is of more concern because of the potential for secondary gain. While the BDI-II is an accepted method of evaluating an individual's level of symptoms over time, self-report in isolation is not an acceptable method of diagnosing depression. In order to ensure that patients' psychiatric symptoms are accurately classified, a thorough psychiatric interview must be conducted, and a second blind evaluator would add some credibility.

That being said, this is an intriguing report, which fits with our clinical impression. Obviously further work is merited on this important observation.

ALASTAIR CARRUTHERS, FRCPC  
*Vancouver, Canada*

MARILYNN HAMMOND, MD  
*Daphne, AL*